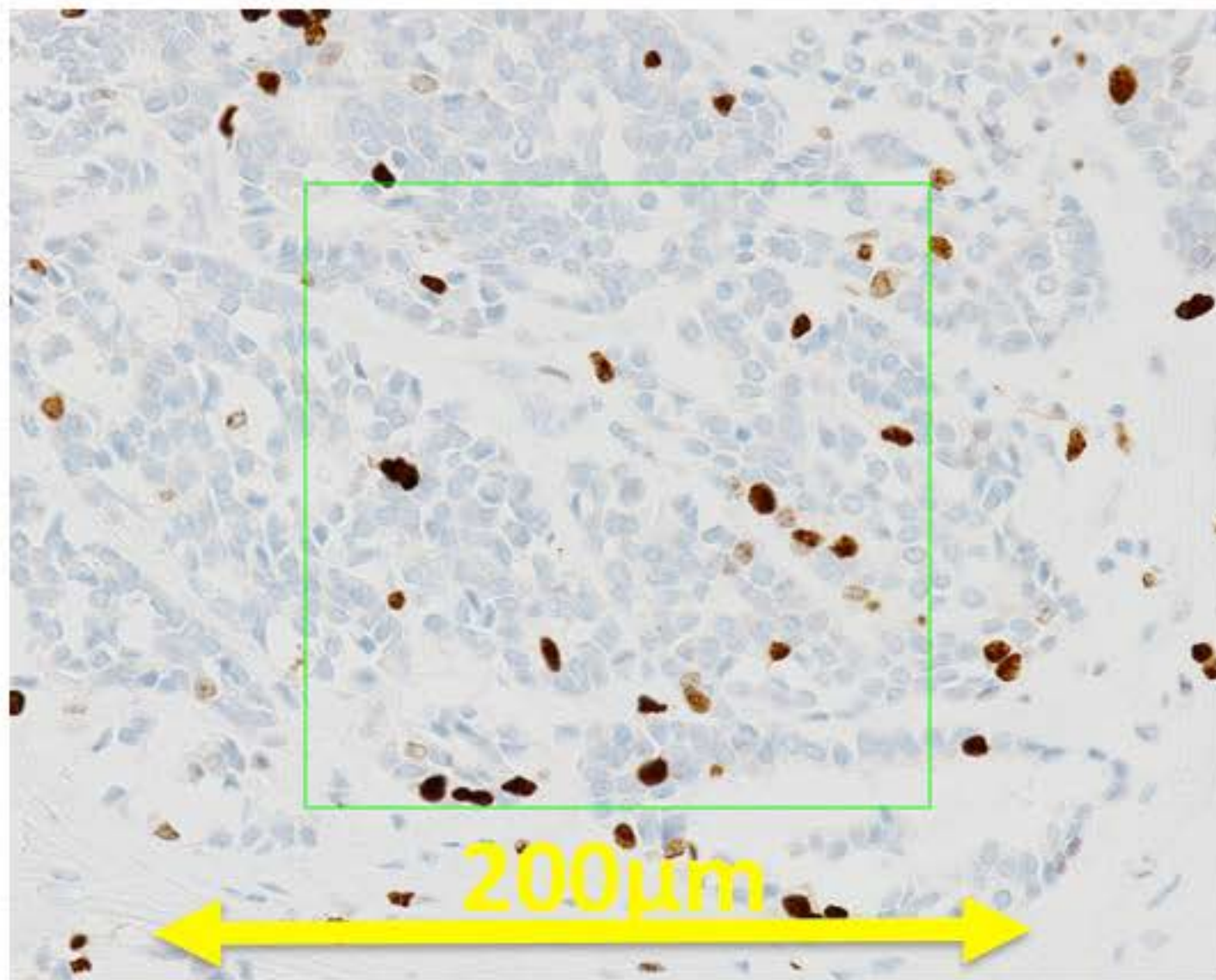
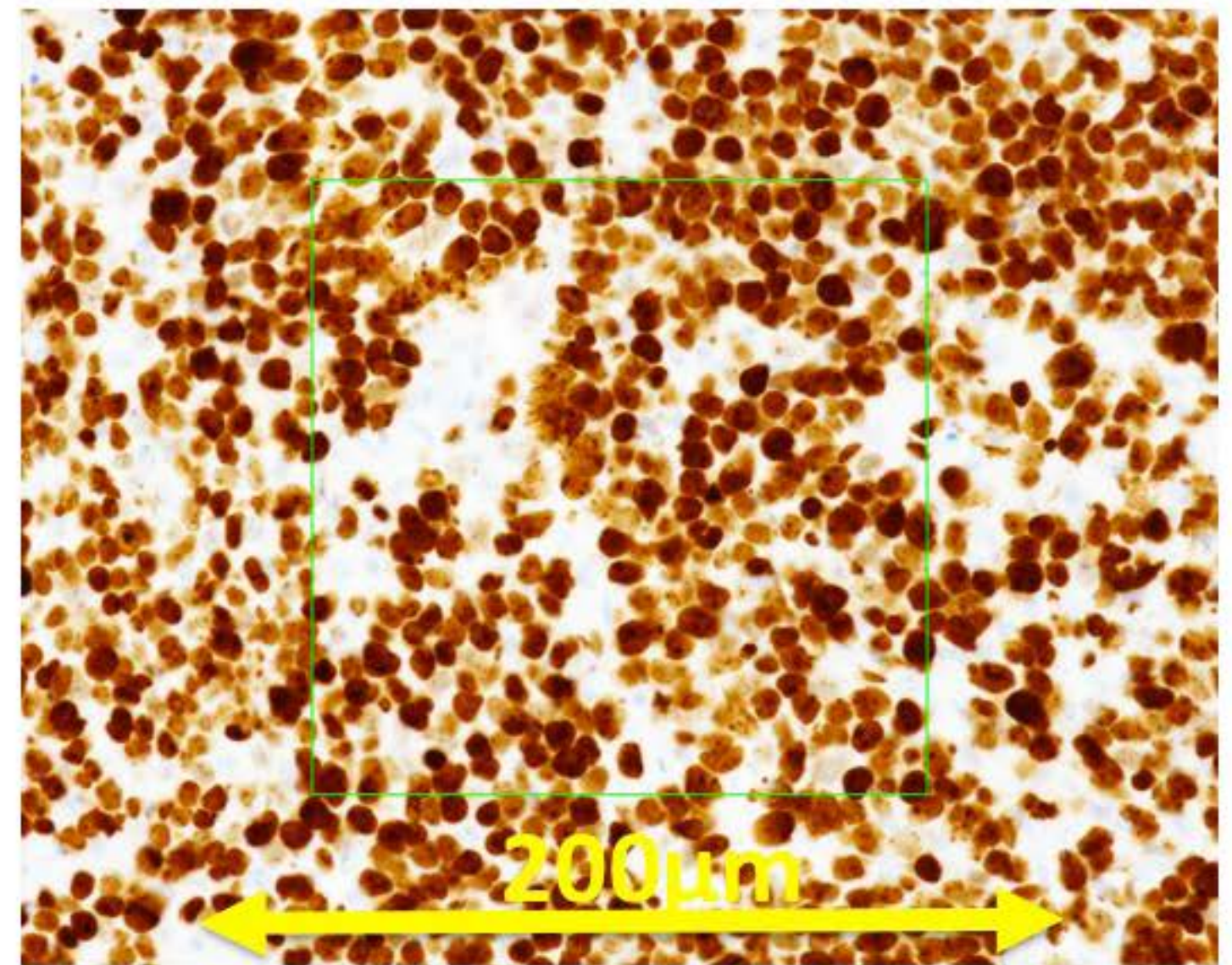


# 癌組織の比較(Ki-67染色)



Breast cancer; Invasive ductal carcinoma, scirrhous



Malignant lymphoma; diffuse large B cell lymphoma